

A Comparative Study Between Alexandrite Laser and Intense Pulsed Light in Axillary Hair Removal

AHMAD S. EL-BADAWI, M.D.*; MAHA A. SHAHEEN, M.D.**; HAZEM M. MAHER, M.D.* and MAY HUSSEIN EL-SAMAHY, M.D.**

The Departments of Plastic & Reconstructive Surgery and Dermatology**, Faculty of Medicine, Ain Shams University.*

ABSTRACT

Alexandrite laser and intense pulsed light (IPL) are now used worldwide for prolonged and permanent hair removal. The hair removal mechanism of both techniques is based on their selective photo thermolysis that target melanin pigment within the hair follicles. The study aimed at evaluation of the efficiency and side effects of single treatment using Alexandrite laser and intense pulse laser in axillary hair removal. The study included 8 female patients. IPL was applied on the right side while Alexandrite laser on the left side. Histopathological examination of biopsy specimen together with hair count prior, immediately and after 3 months of treatment were done. Morphological and Histopathological examination of biopsy specimen revealed that both techniques are efficient without complication.

INTRODUCTION

Excessive hair growth as seen in hypertrichosis and hirsutism is cosmetically undesirable. Temporary hair removal methods such as shaving, tweezing, plucking, waxing and chemical depilatories are several commonly employed methods but they may cause irritation and are only partially effective [1].

Until recently, electrolysis was the only method for long-lasting hair removal; however, it is time consuming, somewhat painful and operator dependent and has an estimated efficacy of 15 to 50% permanent hair loss [2].

The use of laser and IPL for the removal of unwanted or excess body hair has been recently introduced in clinical practice, gaining popularity among patients and physicians [3].

The most commonly used lasers for hair removal are the Ruby, Alexandrite, Diode and Nd: YAG (1064 nm) [4].

The Ruby laser with a wavelength of 694 nm has the shortest penetration depth and the most selective absorption by melanin. The Nd: YAG

laser, emitting in the infrared at 1064 nm, has the deepest depth of penetration but the least selective absorption. The Alexandrite (755-nm) and Diode (810-nm) lasers sit between these extremes [4].

The IPL uses incoherent light of a broadband spectrum in the range of 600 to 1200 nm. The use of different cut-off filters allows adjusting the treatment parameters to the patient's skin type and hair color [5].

The goal of laser or flashlamp photoepilation is to produce long-term, or permanent, cosmetically significant hair removal. The major proposed mechanism of action is "selective photothermolysis", with follicular melanin as the major target chromophore. Wavelengths in the red and infrared range (600-1200 nm) of the electromagnetic spectrum are optimal for this goal [6].

Melanization of the hair follicle has been shown to be maximal during the anagen phase. It has been proposed that efficiency of photoepilation may be optimal during this phase [6].

The resulting follicular damage depends on a host of factors, including the degree of pigmentation and size of the target follicle, the selected wavelength, fluence, spot size, pulse duration and the hair cycle at the time of treatment [7].

Lasers and IPL induce a temporary complete hair loss, which seems to be caused by induction of telogen in growing hairs [3]. However, the regrowing hair is generally thinner and lighter than the original hair [8].

The key factors in reducing the number of complications associated with laser-assisted hair removal are proper patient selection and tailoring of the fluence used to the patient's skin type. The

ideal patient for laser hair removal is fair skinned with dark-pigmented hair [9].

Adverse effects reported after laser-assisted hair removal include erythema and perifollicular edema, which are common and crusting and vesiculation of treatment site, hypopigmentation and hyperpigmentation (depending on skin color and other factors). Most complications are generally temporary [10,12].

IPL may lead to side effects, most of which are minimal and transient. They include erythema, superficial burning, vesicle and crust formation, pigmentary alterations, local heat sensation, bacterial infection and pain. Permanent side effects (i.e., scars, pigmentary alteration) rarely occur but patients should be warned about them [11].

The aim of our study is to evaluate the efficacy and side effects of single treatment using Alexandrite laser and intense pulsed light source and to compare results of both treatment modalities in axillary hair removal.

MATERIAL AND METHODS

The devices used were:

I- Alexandrite laser: (Fig. 1)

The device (95 kg), as shown, consists of flash lamp-excited solid state Alexandrite laser the wavelength of which is 755 nm. The output of the laser is delivered through an optical fiber delivery system to hand piece. The maximum delivery energy is 53 joules with pulse duration 3 msec. The beam spot sizes diameter 6/8/10 mm and 12/15/18 mm. The laser system is provided with skin cooling device referred to as the dynamic cooling device (DCD). The DCD consists of an electrically controlled spray nozzle located at the treatment end of the hand piece.

II- Novalight controlled pulsed light (CPL) technology: (Fig. 2)

It is a 3rd generation intense pulsed light system (IPL). The device as shown comprises 15 kg portable CPL equipped with a single hand piece. The lamp is a straight type with no need for pre-ignition; light is transmitted through quartz to spot size of 5.2 x 1.5 cm. It has three types of cap-shaped filters, for hair of dark skin photo type patient. An ultrasound gel should be applied for optical coupling. The pulse durations range from 70 msec to 240 msec and the fluency setting range from 8-20 J/cm².

The present study was conducted on eight healthy females seeking permanent axillary hair

removal. They were selected from the Dermatology and Venereology Department at Ain Shams University Hospital in the period from June to December 2003.

Their ages ranged between 18 and 48 years with a mean of 33 years. Their Fitzpatrick skin types were: skin type II (two patients), skin type III (three patients) and skin type IV (three patients).

From each subject a proper history was taken excluding pregnancy, active local infections, chronic or uncontrolled systemic diseases, history of keloid formation or hypertrophic scarring, history of hypersensitivity or systemic medications known to be photo-sensitizing. Each subject was examined clinically to exclude any of the above exclusions.

In each subject one hair removal treatment session was performed using an intense pulsed light source (NOVA light) on the right axilla and using an Alexandrite laser (Gentle LASE) for hair removal on the left axilla.

Both treatments were performed on the same day. As regards the Alexandrite laser, the fluence was adjusted between 16-20 J/cm² according to the skin type. The spot size was 18 mm of 2 msec duration. The dynamic cooling device (DCD) spray duration was 60 msec with a delay of 70 msec.

Regarding the IPL, its fluence was adjusted between 18-26 J/cm² according to the skin types. A spot size 25 x 15 mm was used with pulse duration 20-30 msec with a delay of 4 sec. A transparent non-alcoholic gel was applied to the surface prior to treatment.

Pre-operative preparation:

1- Skin preparation:

Sunbath and the use of UVA tanning was not allowed two weeks before treatment.

2- Hair preparation:

All patients were instructed to stop all hair removal methods apart from shaving several weeks before treatment. Waxing tweezing or bleaching is allowed 2 weeks before or after the procedure. It is important not to pluck or wax the hair shortly before treatment, as this would remove intended target from the hair follicle.

Plucking or waxing of hair shafts prior to laser treatment significantly reduces the effectiveness for long-term hair loss, but does not affect temporary hair loss. The hair was shaved immediately before the session.

3- Anesthesia:

Alexandrite laser is accompanied by dynamic cooling device and a cooling gel was applied before IPL so only a slight stinging sensation was experienced which can usually be tolerated by patients without anesthesia.

4- Laser safety precautions:

During treatment everyone in the laser room used protective eye wear appropriate to the wavelength emitted by the light system.

A saline moistened gauze was used under opaque patient goggles to ensure that the patient's eyes remain closed during treatment. The laser used for hair removal penetrates deeply in the tissue where melanin pigment is the target. The retina has pigment that can be severely damaged without appropriate protection.

The laser beam was not allowed to be directed at anything other than the targeted area. Inflammable substances as alcohol and acetone were not used in preparing the skin for treatment. Water was used instead to clean and remove ointments. Plume evacuation systems should be in place and functioning. It is unclear at this time if the plume from hair removal is harmful. Plume evacuation will also help to reduce the odour that occurs from vapourized hair. During treatment, overlapping of pulses was avoided.

Postoperative care:

When sufficient energy has been delivered and absorbed by the hair follicle, perifollicular swelling and redness are usually visible within 3 to 5 minutes which are desired clinical endpoints. If this reaction doesn't occur, the fluence can be increased within a safe range for that skin type.

After treatment the majority of patients experienced mild sunburn like sensation which typically disappears without treatment in 2 to 3 hours.

1- Cooling:

After each treatment, topical cryoesthesia using ice bag was applied to the area so as to give relief and reduce the swelling duration.

2- Topical therapy:

A moisturizer applied in circular motions can aid in decreasing the sun burn like sensations. A topical corticosteroid cream was used to decrease the acute inflammation and erythema as well as post-inflammatory changes. Antibacterial agent was prescribed for fear of consequences of epidermal damage that might happen.

3- Sun avoidance:

Sunbath and the use of UVA tanning was avoided two weeks after treatment.

4- Other instructions:

Patients were instructed to clean the treated sites gently twice daily. No harsh soaps, scrubs, glycolic or retinoic acid-containing products or manipulation of the treated areas are permitted.

Patients were instructed to stop plucking, waxing or bleaching of hair in the treated area 2 weeks after the procedure.

Evaluation of both treatment procedures:

A 3 mm punch biopsy was obtained from each axilla immediately after and three months after photoepilation and stained with HX and Eosine to evaluate:

- 1- Depth of penetration.
- 2- Percentage of destructed follicles.
- 3- Histopathological changes of the destructed hair follicle.
- 4- Presence of signs of keratinocytes cellular proliferation.

The following DATA were recorded for each procedure:

- 1- Pain during treatment.
- 2- Immediately post treatment complications (edema, erythema, blistering and pain).
- 3- Late post treatment complications (infection, dyspigmentation and scarring).
- 4- Treatment outcome regarding % hair reduction 3 months after treatment.

Pre-treatment and 3 months post-treatment hair counts were performed using a standardized 1 cm² grid with the aid of a hand lens, the difference between pre and 3 months post-treatment hair counts were calculated and put in the form of a percentage.

RESULTS

The patients range in age from 18 to 48 years (mean age 33 years). Two case with skin type II, three cases with skin type III and three cases with skin type IV.

The average number of pulses performed by Alexandrite (11.5) is more than the number performed by IPL (6.75) in treating any given area due to difference in spot size between Alexandrite (18 mm) and IPL (52x15 mm).

The above data shows that 60% of our patients developed tolerable pain during laser treatment regardless of skin type while IPL was painless.

The immediate post treatment complications in form of mild transient erythema and perifollicular edema were seen immediately after photoepilation regardless of fluence used.

Slight discomfort was experienced but more in the left axilla treated with Alexandrite laser than on the right axilla treated with IPL. There was no evidence of late post treatment complication in the form of infection, dyspigmentation or scarring in any of the treated patients.

From the above data it is observed that hair reduction depended on the hair color and skin type.

Punch biopsies taken immediately after laser treatment shows damaged coagulated hairs within hair follicles as well as a variable amount of inflammation and pigmentary incontinence. Hair shaft shows fragmentation with focal rupture into the follicular epithelium and thermal damage to the surrounding follicular epithelium. Clumping of melanin, distortion of hair shaft and homogenization of the keratin layer in hair follicles with coagulative necrosis of hair shaft and thinning of follicular epithelium (Figs. 3,4,5).

While biopsies taken three months after single treatment revealed vacuolization of keratinocytes with separation at the dermo-epidermal junction, necrotic keratinocytes follicular miniaturization and fewer numbers of terminal hairs in all biopsy specimens, irrespective of the fluence used (Figs. 6,7,8).

Morphologic alterations were not identified in other skin adnexa, overlying epidermis, vessels, or other dermal structures in all cases examined.

Table (1): Fluence was adjusted according to the skin type as in the following as regard Alexandrite laser and IPL.

Case	Skin type	Laser (fluence)	IPL (fluence)
Case 1	II	20 J/cm ²	26 J/cm ²
Case 2	III	18 J/cm ²	24 J/cm ²
Case 3	III	18 J/cm ²	24 J/cm ²
Case 4	IV	16 J/cm ²	18 J/cm ²
Case 5	IV	16 J/cm ²	18 J/cm ²
Case 6	III	18 J/cm ²	24 J/cm ²
Case 7	II	20 J/cm ²	26 J/cm ²
Case 8	IV	16 J/cm ²	18 J/cm ²

Table (2): Number of pulses performed by each light system.

Case	Alexandrite laser	IPL
Case 1	10	6
Case 2	12	7
Case 3	14	8
Case 4	10	6
Case 5	12	7
Case 6	12	7
Case 7	10	6
Case 8	12	7
Mean	11.5	6.75

Table (3): Evaluation of pain during treatment (No pain, tolerable pain, intolerable pain).

Case	Alexandrite laser	IPL
Case 1	Tolerable pain	No pain
Case 2	No pain	No pain
Case 3	Tolerable pain	No pain
Case 4	No pain	No pain
Case 5	Tolerable pain	No pain
Case 6	No pain	No pain
Case 7	Tolerable pain	No pain
Case 8	Tolerable pain	No pain

Table (4): Treatment outcome regarding percentage of hair reduction 3 months after one treatment session.

Case	Skin type	Hair color	Alexandrite laser	IPL
Case 1	II	Black	60%	50%
Case 2	III	Black	50%	60%
Case 3	III	Brown	40%	40%
Case 4	IV	Brown	40%	30%
Case 5	IV	Brown	30%	30%
Case 6	III	Black	50%	60%
Case 7	II	Black	60%	50%
Case 8	IV	Black	40%	30%
Mean			52%	49%



Fig. (1): Alexandrite laser device.



Fig. (2): NOVA light controlled pulsed light (CPL) technology device.

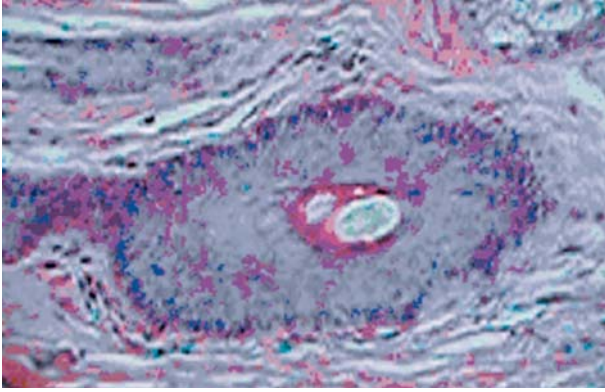


Fig. (3): Section of biopsy specimen immediately after laser treatment showing coagulated hairs in follicles (Hx & E magnification x 10).

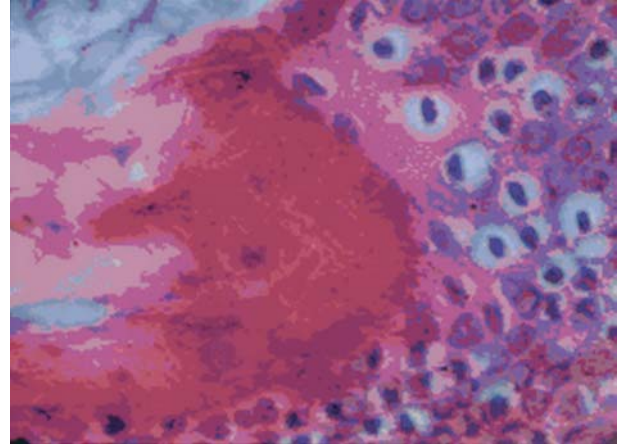


Fig. (6): 3 months after IPL-treatment. This hair follicle has contains necrotic keratinocytes (catagen phase) (Hx & E magnification x 100).

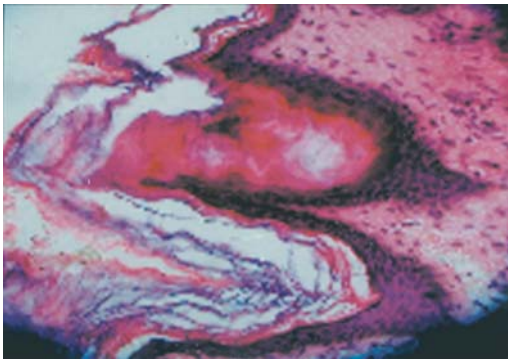


Fig. (4): Section of a biopsy specimen immediately after IPL treatment showing, distortion of hair shaft and homogenization of the keratin layer in hair follicles with coagulative necrosis of hair shaft and thinning of follicular epithelium (Hx & E magnification x 40).

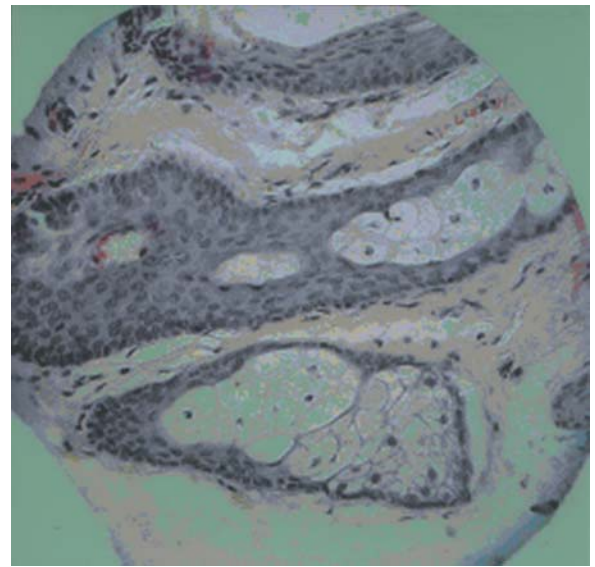


Fig. (7): Biopsy specimen 3 months after Alexandrite laser treatment showing distorted hair follicle and miniaturization (Hx & E magnification x 40).

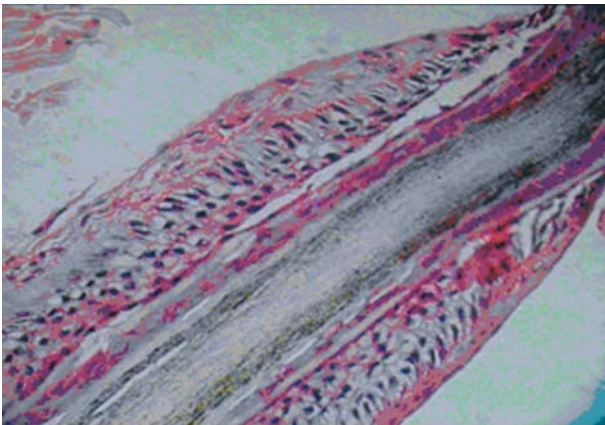


Fig. (5): Section of biopsy specimen 12 weeks after Alexandrite laser treatment. There is vacuolization of keratinocytes with separation at the dermoepidermal junction (Hx & E magnification x 40).

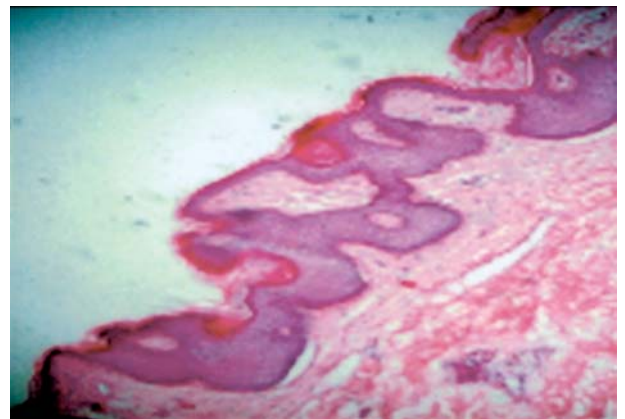


Fig. (8): Section of biopsy taken 3 months after IPL treatment showing decreased number of terminal hair without any alteration in dermis or vessels follicles (Hx & E magnification x 10).

DISCUSSION

The NOVA light method uses controlled intense pulsed light as its source of power, whereas lasers employ an extremely condensed beam of light that delivers a lot of energy in a short period of time. In laser, the temperature can rise up to 700°C (1292°F) and can cause burns and pigmentation problems if not used with extreme caution. Furthermore, such temperature give rise to excessive penetration that can cause alterations in the dermis as well as pain that can only be allayed through the application of cold or topical anesthetics [10].

In the present study, Alexandrite laser is supplied with dynamic cooling system (DCD) that allows cooling and protection of the epidermis before laser beam reaching the skin so no overheating was done.

In contrast, the NOVA light CPL method uses polychromatic wave spectrum distributed over an area of 7 cm² and achieves a controlled temperature increase only to above 70°C (158°F) that has being more than enough to breakdown the proteins that make up the bulb and adjacent blood vessels without harming the skin.

The IPL has several distinct advantages over lasers, mainly arising from its flexibility in allowing a wide range of settings relating to individual patient characteristics. For the same reasons, it is an effective tool in the hands of an experienced specialist [5].

The present study included eight healthy females seeking permanent axillary hair removal of different skin types (25% Type II, 37.5%, Type III, 37.5% Type IV) [14].

Nanni and Alster [12] used no preoperative skin care regimen particularly the prophylactic bleaching program. In the present study also no routine course or any kind of preparation was done to the patient prior to treatment. On the other hand some authors pretreated their patients with hydroquinone and tretinoin for a period of 3 weeks. It is thought that hydroquinone can depigment melanosomes at the dermo-epidermal junction and along the distal hair shaft, but is unlikely to affect pigmentation at the level of the proximal hair shaft, bulge and hair bulb area. Therefore, it is unlikely that the depigmentation would affect the treatment efficacy of laser hair removal [6].

Liew et al., [6] instructed all patients to stop all other hair removal methods apart from shaving. The hair was trimmed immediately before the session to be with 1 to 2 mm protruding from the

skin surface. In the present study, same instructions were given to the patients with trimming of hair prior to the session. Greater hair loss has been showed at shaved versus epilated sites, suggesting that light absorption by the pigmented hair shaft itself plays an important role.

Liew et al., [6] stated that laser targets coarse hair more than fine hair due to two reasons. First, coarser hairs have higher melanin content than finer hairs. Secondly, coarser hair loose heat more slowly than finer hairs because of their smaller surface area to volume ratio. It was easier to treat fine hair compared with coarse hair because coarse hair often has a thick layer of keratin and requires a higher energy level for removal. However, we did not use higher energy levels, as they would have resulted in more side effects, such as scar formation and hypopigmentation.

Certain areas of the body as the chin and back tend to be less responsive to treatment due to having thicker skin [15]. However, in the present study we are treating the axilla which have thin non-keratinized skin.

Pain during treatment increased with increasing fluence and in those patients with darker hair [16]. In the present study most of the patients experienced tolerable pain with Alexandrite laser while no pain developed with IPL may be due to the cooling gel applied before the procedure which agreed with a study performed by Moreno-Arias et al. [11] which stated that IPL photodepilation it is a painless procedure.

Grossman [8] reported that after treatment, the majority of patients will experience a mild, sunburn-like sensation that typically disappears without treatment in 2 to 3 hours. This sensation is proportional to the degree of pigment in the hair and/or skin. This agrees with the transient erythematous reaction with perifollicular edema which was noted in the present study. However, Gault et al., [15] reported that the condition might persist for 2 to 3 days after treatment in face and up to 7 days in the trunk. Liew et al., reported a period of 1-3 days for extremities [6]. Raulin et al., stated that Post-treatment perifollicular erythema and edema are to be expected in all patients. When threshold fluences were used. The intensity and duration depend on hair color and hair density and may last for 3 days [3].

Nevertheless, adverse effects were limited in severity at any fluences and were generally transient with no residual scarring or permanent discoloration noted.

In the present study no blistering or crusting was noted after laser or IPL treatment. There was no hypo or hyperpigmentation occurred in any of the patients skin type (II-IV). This is probably due to the dynamic cooling device equipped within the Alexandrite laser and cooling gel applied before IPL in this study. This agreed with the study by Lanigan in 2000 which reported that for skin type III, the incidence of blistering, hypopigmentation and hyperpigmentation was 0%.

The result of the present study showed that there was no evidence of late post treatment complications in form of infections, atrophy or scarring in any of the treated patients. This is contrary to the previous reports that showed pigmentary changes and blistering in up to 14 and 15% respectively of treated patients by alexandrite laser and especially in women with darker skin types due to the abundance of melanin in their epidermis. The increased epidermal melanin seen in patients with darker skin tones serves as a competing chromophore and facilitates absorption of energy in the skin [13,17].

In the present study 44% hair reduction was noted at 3 months after a single treatment by laser which agreed with Hussain et al., [22].

Other study done by Nanni and Alster [12] has shown approximately 71% to 85% hair reduction after a series of long-pulsed 755-nm Alexandrite laser treatments in patients with skin phototypes I-IV after six months from the last treatment.

In the present study hair reduction of 42% after a single treatment with IPL was noted after 12 weeks follow up. This agreed with Weir and Woo [18]. However, Gold et al., noticed that 60% hair reduction was achieved 12 weeks after single treatment [19].

Liew et al., [20] noted 37% hair reduction after single treatment with three months follow up [6]. After one treatment by IPL, hair clearance of 52% is seen after 12 weeks.

Using a single treatment of IPL, hair reductions ranging from 33 to 60% are observed at 6 months after treatment [19,20]. In another study, after a mean of 8 (range of 2 to 23) treatments, an average of 87% hair reduction was achieved [5]. Patients with very dark hair and very light skin have the best outcome [18].

In the present study we noticed that hair became thinner than before and regrow in a slow manner yielding better cosmetic appearance and satisfaction

to the patient. Grossman et al., pointed out the fact that the regrowing hair in laser treated areas is finer than in other adjacent non treated areas [21]. The growing hair may become thinner due to permanent destruction of some progenitor hair cells that gave rise to new hair formation [6].

Weiss and Cohen [14] noted that in patients where treatment did not reduce hair density, they commented that hair were finer, softer and grow at a slower rate after treatment.

Liew et al., [6] stated that although the mean diameter was reduced at 3 months, the diameter return to normal after 7 months. In the present study positive results were recorded with the follow up ending at three months not knowing if the hair would revert to its original thickness or not.

The number of treatments required to obtain a cosmetically accepted result varies among patients. Most patients require more than one treatment to achieve nearly complete permanent hair reduction.

The treatment was timed so that the largest numbers of hairs are in the anagen phase where the stem cells become metabolically active and the melanocytes are actively synthesizing melanin as stated by Nanni and Alster [12].

Kolinko and Littler [15] on the other hand stated that laser-induced reduction in hair diameter and/or pigmentation are both long-term responses which confer benefits in addition to actual hair loss.

Despite the re-growth of hair, patient satisfaction after IPL and laser-assisted hair removal remains high compared with other hair removal methods. This may be related to a variety of factors, which include relatively pain-free treatment, a long hair-free interval, thinning of the hair and a low incidence of adverse effects [6].

Histopathological changes of hair follicle immediately after Alexandrite Laser and IPL showed coagulated hairs within hair follicles as well as a variable amount of inflammation and pigmentary incontinence and after 3 month miniaturization and fewer numbers of terminal hairs in all biopsy specimens were noticed. Also, treatment did not alter other skin adnexa, epidermis, or vessels. This agreed with Nanni and Alster, [17].

There is no evidence of cellular hyperproliferation which agreed with the study performed by Liew et al., stated that despite the possible microscopic damage seen in the basal epidermis after laser hair removal, which is reassuring sign that treatment is safe [6].

The 755 nm alexandrite laser has excellent melanin absorption, which makes it desirable and effective for lighter, thinner hairs seen in skin type I and II patients. But it scatters more than longer wavelengths as it penetrates through the dermis. The use of a large spot size (18 mm) as in the present study seems to deliver a sufficient "effective fluence" to its target 3-4 mm into the dermis. In a prospective study, Eremia and Newman [16] demonstrated that at equal skin surface measured fluences (20-40 J/cm²), a 12 mm spot size yields a two to three times greater long-term hair reduction after three to four treatments than an 8 mm spot size.

The size of the IPL head (52x15 mm) plays an important role in improving light penetration into the tissue because the large spot size diminishes the scattering [5].

From the present study, we conclude that laser and IPL proved to be effective and safe in hair reduction. Though Alexandrite laser is the most currently used laser nowadays, the use of IPL is expected to increase due to its promising results.

REFERENCES

- 1- Marchell N.L. and Alster T.S.: Evaluation of temporary and permanent hair removal methods. *J. Aesth. Cosmet. Dermatol. Surg.*, 1: 3-12, 1999.
- 2- Wanger R.F.: Medical and technical issues in office electrolysis and thermolysis *J. Dermatol. Surg. Oncol.*, Vol. 19, p. 575, 1993.
- 3- Raulin C., Werner S., Hartschuh W. and Schonermark M.P.: Effective treatment of hypertrichosis with pulsed light: a report of two cases. *Plast. Surg.*, 39: 169-173, 1997.
- 4- Sommer S., Render C. and Sheehan-Dare R.: Facial hirsutism treated with the normal-mode ruby laser: results of a 12-month follow-up study. *J. Am. Acad. Dermatol.*, 41: 974-979, 1999.
- 5- Schroeter, Careen A., Groenewegen, Jan S., Reineke, Thorsten, Neuman and Herman A.M.: Hair reduction using intense pulsed light. *Dermatol. Surg.*, 30 (2): 168-173, 2004.
- 6- Liew S.H., Grobelaar A.O., Gault D.T., et al.: Ruby laser hair removal: clinical efficacy in Fitzpatrick skin type I-V and histological changes in epidermal melanocytes. *Br. J. Dermatol.*, 140: 1105-9, 1999.
- 7- Touma, Dany J., Rohrer and Thomas E.: Persistent hair loss 60 months after a single treatment with a 3-millisecond alexandrite (755 nm) laser. *J. Am. Acad. Dermatol.*, 50 (2): 324-325, 2004.
- 8- Grossman M.C.: Hair removal. From: cutaneous laser surgery. 2nd ed. Edited by: Goldman M.P. and Fitzpatrick R.E. Chap. 5, p. 259-278. Mosby, Inc., 1999.
- 9- Andersen and Karen R.N.: Laser technology a surgical tool of the past, present and future. *AORN J.*, Volume 78 (5): 794-802, 805-807, November, 2003.
- 10- Lanigan S.W.: Indence of side-effects after laser removal of hair. *Br. J. Dermatol.*, 147, 25, 2000.
- 11- Moreno-Arias G.A., Navarra E., Vilalta A., Ferrando J.: Corrective photoepilation for improper hairline placement after hair transplantation. *Dermatologic Surgery*, 26 (8): 790-2; Discussion 792, 2000.
- 12- Nanni C.A. and Alster T.S.: Laser-assisted hair removal; side effects of Q-switched Nd: YAG, long-pulsed ruby and alexandrite lasers. *J. Am. Acad. Dermatol.*, 41: 165-171, 1999.
- 13- MacCoy S., Evans A., James C.: Histological study of hair follicles treated with a 3 msec pulsed ruby laser. *Lasers Surg. Med.*, 24: 142-50, 1999.
- 14- Weiss G. and Cohen B.: The efficacy of long-term epilation of unwanted hair by noncoherent filtered flashlamp. *Lasers in Surgery and Medicine*, 26 (4): 345, 2000.
- 15- Kolinko V. and Little C.M.: Mathematical modeling for the prediction and optimization of laser hair removal. *Lasers Surg. Med.*, 26: 164-76, 2000.
- 16- Eremia S. and Newman N.: Topical anesthesia for laser hair removal: comparison of spot sizes and 755 nm versus 800 nm wavelengths. *Dermatol. Surg.*, 26: 667-9, 2000.
- 17- Nanni C.A. and Alster T.S.: Optimizing treatment parameters of or hair removal using a topical carbon-based solution and 1064-nm Q-switched neodymium: YAG laser energy. *Arch. Dermatol.*, 133: 1546-1549, 1997.
- 18- Weir V.M. and Woo T.Y.: Photo-assisted epilation: review and personal observations. *J. Cutan Laser Ther.*, 1: 135-143, 1999.
- 19- Gold M.H., Bell M.W., Foster T.D. and Street S.: Long-term epilation using the EpiLight Broad Band, intense pulsed light hair removal system. *Dermatol. Surg.*, 23: 909-913, 1997.
- 20- Weiss R.A., Weiss M.A. and Marwaha S.: Hair removal with a non-coherent filtered flash-lamp pulsed light source device. *Am. Soc. Laser Med. Surg.*, 10: 40, 1998.
- 21- Grossman M.D., Yung R. and Berlin A.J.: Prospective evaluation of the argon laser in the treatment of trichiasis. *Ophthamol. Surgery*, Vol. 23, p. 183-187, 1992.
- 22- Hussain, Mussarat, Polnikorn, Niwat, Goldberg and David J.: Laser assisted hair removal in Asian. *Dermatol. Surg.*, 29 (3): 249-254, 2003.